

## Practice guidelines for performance of the routine mid-trimester fetal ultrasound scan

L. J. SALOMON, Z. ALFIREVIC, V. BERGHELLA, C. BILARDO, E. HERNANDEZ-ANDRADE, S. L. JOHNSEN, K. KALACHE, K.-Y. LEUNG, G. MALINGER, H. MUNOZ, F. PREFUMO, A. TOI and W. LEE on behalf of the ISUOG Clinical Standards Committee

### Clinical Standards Committee

The International Society of Ultrasound in Obstetrics and Gynecology (ISUOG) is a scientific organization that encourages sound clinical practice, teaching and research for diagnostic imaging in women's healthcare. The ISUOG Clinical Standards Committee (CSC) has a remit to develop Practice Guidelines and Consensus Statements as educational recommendations that provide healthcare practitioners with a consensus-based approach for diagnostic imaging. They are intended to reflect what is considered by ISUOG to be the best practices at the time at which they were issued. Although ISUOG has made every effort to ensure that guidelines are accurate when issued, neither the Society nor any of its employees or members accepts any liability for the consequences of any inaccurate or misleading data, opinions or statements issued by the CSC. They are not intended to establish a legal standard of care because interpretation of the evidence that underpins the guidelines may be influenced by individual circumstances and available resources. Approved guidelines can be distributed freely with the permission of ISUOG (info@isuog.org).

### INTRODUCTION

Ultrasonography is widely used for the prenatal evaluation of growth and anatomy as well as for the management of multiple gestations. The procedure provides diagnostic findings that often facilitate the management of problems arising in later pregnancy. For example, abnormal fetal growth is a leading cause of perinatal morbidity and mortality in both industrialized and developing countries. In 2005, the World Health Organization (WHO) concluded that impaired fetal growth had many causes related to: genetic factors, maternal characteristics such as nutrition, lifestyle including smoking, age and disease; complications of pregnancy; and the physical, social and economic environment<sup>1,2</sup>. A mid-trimester fetal ultrasound scan

serves as an important baseline against which later scans may be compared for the evaluation of growth and health. Ultrasonography can also be used to detect congenital anomalies<sup>3-6</sup>. The Eurofetus study<sup>7</sup>, a multicenter project involving 61 obstetric ultrasound units from 14 European countries, examined the accuracy of routine mid-trimester ultrasonographic examination in unselected populations. Over one half (56%) of 4615 malformations were detected and 55% of major anomalies were identified before 24 weeks of gestation.

Although many countries have developed local guidelines for the practice of fetal ultrasonography, there are still many areas of the world where they have not been implemented. Most countries offer at least one mid-trimester scan as part of standard prenatal care, although obstetric practice varies widely around the world. This can be related to the availability of qualified practitioners and equipment, local medical practice and legal considerations; in some countries, insurance-related cost reimbursements strongly influence how routine mid-trimester scans are implemented. Nonetheless, a WHO Study Group stated: 'Worldwide, it is likely that much of the ultrasonography currently performed is carried out by individuals with in fact little or no formal training.'<sup>8</sup>. The intent of this document is to provide further guidance for healthcare practitioners in the performance of the mid-trimester fetal ultrasound scan.

### GENERAL CONSIDERATIONS

#### What is the purpose of a mid-trimester fetal ultrasound scan?

The main objective of a routine mid-trimester fetal ultrasound scan is to provide accurate diagnostic information for the delivery of optimized antenatal care with the best possible outcomes for mother and fetus. The procedure is used to determine gestational age and to perform fetal measurements for the timely detection of

growth abnormalities later in pregnancy. Other goals are to detect congenital malformations and multiple pregnancies.

Prenatal screening examination includes an evaluation of the following:

- cardiac activity;
- fetal number (and chorionicity if multiple pregnancy);
- fetal age/size;
- basic fetal anatomy;
- placental appearance and location.

Although many malformations can be identified, it is acknowledged that some may be missed, even with sonographic equipment in the best of hands, or that they may develop later in pregnancy. Before starting the examination, a healthcare practitioner should counsel the woman/couple regarding the potential benefits and limitations of a routine mid-trimester fetal ultrasound scan.

#### **Who should have a mid-trimester fetal ultrasound scan?**

Many countries offer at least one routine mid-trimester fetal ultrasound scan. As one example, an imaging workshop organized by the Eunice Kennedy Shriver National Institute of Child Health and Human Development in the United States<sup>9</sup> reached a consensus that all pregnant women should be offered an ultrasound scan for the detection of fetal anomalies and pregnancy complications. Serial scans may be helpful for some mothers with risk factors for adverse pregnancy outcome (e.g. hypertension or diabetes) and others may benefit from more detailed scans that are targeted to their specific situation. Repeated or detailed examinations, however, are not considered to be routine scans.

#### **When should the mid-trimester fetal ultrasound scan be performed?**

A routine mid-trimester ultrasound scan is often performed between 18 and 22 weeks of gestation. This period represents a compromise between dating the pregnancy (more accurate if established earlier) and the timely detection of major congenital anomalies. Countries where pregnancy termination is restricted should balance detection rates against the time needed for counseling and additional investigation. Some centers perform the anatomical survey using transvaginal scanning at approximately 13–16 weeks' gestation. This earlier approach can provide useful information about gestational age as a baseline for growth assessment or determination of chorionicity for twins, but may require special training for the early interpretation of anatomical structures.

#### **Who should perform the mid-trimester fetal ultrasound scan?**

Individuals who routinely perform obstetric scans should have specialized training for the practice of diagnostic ultrasonography in pregnant women. However, the

requirements for this activity may vary depending on the country.

In order to achieve optimal results from routine screening examinations, it is suggested that scans should be performed by individuals who fulfil the following criteria<sup>10</sup>:

- trained in the use of diagnostic ultrasonography and related safety issues;
- regularly perform fetal ultrasound scans;
- participate in continuing medical education activities;
- have established appropriate referral patterns for suspicious or abnormal findings;
- routinely undertake quality assurance and control measures.

#### **What ultrasonographic equipment should be used?**

For routine screening, equipment should have at least the following:

- real time, gray-scale ultrasound capabilities;
- transabdominal transducers (3–5-MHz range);
- adjustable acoustic power output controls with output display standards;
- freeze frame capabilities;
- electronic calipers;
- capacity to print/store images;
- regular maintenance and servicing, important for optimal equipment performance.

#### **What document should be produced/stored/printed or sent to the referring healthcare provider?**

An examination report should be produced as an electronic and/or a paper document, to be sent to the referring care provider in reasonable time. A sample reporting form is available at the end of this article. Images of standard views (stored either electronically or as printed copies) should also be produced and stored. Motion videoclips are recommended for the fetal heart. Local laws should be followed. Many jurisdictions require image storage for a defined period of time.

#### **Is prenatal ultrasonography safe?**

Prenatal ultrasonography appears to be safe for clinical practice. To date, there has been no independently confirmed study to suggest otherwise. Fetal exposure times should be minimized, using the lowest possible power output needed to obtain diagnostic information, following the ALARA principle (As Low As Reasonably Achievable). More details are available from the ISUOG Safety Statement<sup>11</sup>.

#### **What if the examination cannot be performed in accordance with these guidelines?**

These recommendations represent minimum practice guidelines for the mid-trimester fetal ultrasound scan.

Consideration must be given to local circumstances and medical practices. Reasons for deviations from these recommendations should be documented. If the examination cannot be performed completely in accordance with adopted guidelines, the scan should be repeated, at least in part, at a later time, or the patient can be referred to another practitioner. This should be done as soon as possible, to minimize unnecessary patient anxiety and unnecessary delay in the potential diagnosis of congenital anomalies or growth disturbances.

### What is the role of a more detailed ultrasonographic examination?

Individuals who perform ultrasonographic scans during pregnancy should have referral mechanisms in place to manage suspected or detected abnormalities. A minimum examination, following the guidelines presented herein, should be performed before referring the patient, unless technical factors prevent completion of the initial evaluation.

## GUIDELINES FOR EXAMINATION

### Fetal biometry and wellbeing

The following sonographic parameters can be used to estimate gestational age and for fetal size assessment<sup>12–14</sup>:

- biparietal diameter (BPD);
- head circumference (HC);
- abdominal circumference (AC) or diameter;
- femur diaphysis length (FDL).

Measurements should be performed in a standardized manner on the basis of strict quality criteria<sup>15</sup>. An audit of results can help to ensure accuracy of techniques with regard to specific reference tables. An image(s) should be taken to document the measurement(s). Examples of still images appropriate for fetal biometry are demonstrated in Figure 1.

If gestational age has not already been established at a dating or first-trimester scan, it should be determined

at the mid-trimester scan on the basis of fetal head size (BPD and/or HC) or FDL. The chosen reference standards should be indicated in the report<sup>16</sup>. Subsequent scans should not be used to calculate a new estimated date of confinement if age has already been established by a high-quality scan earlier in the pregnancy. Additional measurements, optimally at least 3 weeks from a preceding scan, are usually reported as deviations from mean values with their expected ranges for a given age. This information can be expressed as Z-scores, percentile reference ranges or on a graph, although the degree of deviation from normal at this early stage of pregnancy that would justify action (e.g. a follow-up scan to assess fetal growth or fetal chromosomal analysis) has not been firmly established.

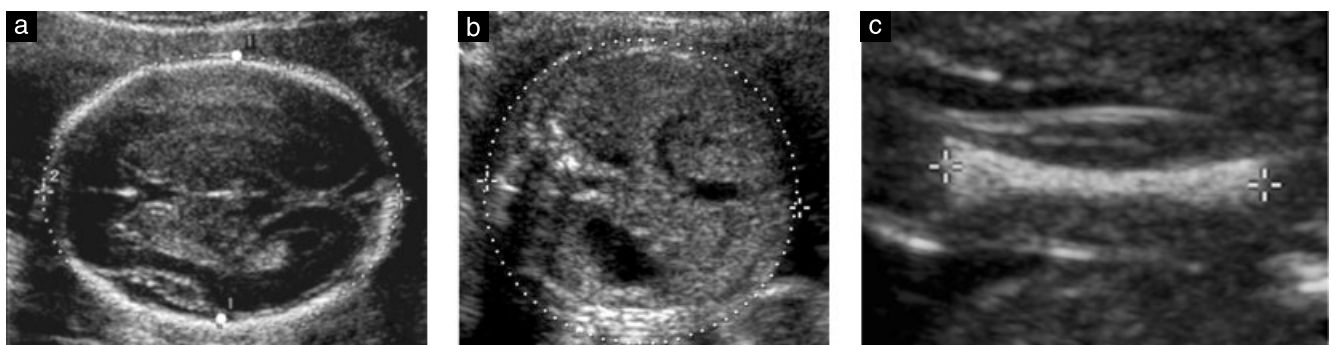
Combining measurements significantly improves accuracy compared with prediction based on HC alone<sup>17</sup>. However, the clinical significance of this improvement is marginal because the improved accuracy represents less than 1 day<sup>18</sup>.

### Biparietal diameter (BPD)

#### Anatomy.

- Cross-sectional view of the fetal head at the level of the thalami;
- ideal angle of insonation is 90° to the midline echoes;
- symmetrical appearance of both hemispheres;
- continuous midline echo (falx cerebri) broken in middle by the cavum septi pellucidi and thalamus;
- no cerebellum visualized.

*Caliper placement.* Both calipers should be placed according to a specific methodology, because more than one technique has been described (e.g. outer edge to inner edge or 'leading edge' technique vs. outer edge to outer edge), at the widest part of the skull, using an angle that is perpendicular to the midline falx (Figure 1)<sup>19</sup>. The same technique as that used to establish the reference chart should be used. The cephalic index is a ratio of the maximum head width to its maximum length and this value can be used to characterize fetal head shape. Abnormal head shape (e.g. brachycephaly and dolichocephaly) can be associated with syndromes. This finding can also lead to inaccurate estimates of fetal age



**Figure 1** Standard fetal biometry: sonographic measurements of the biparietal diameter and head circumference (a), the abdominal circumference (b) and the femur diaphysis length (c). In this example, calipers are placed on the outer and inner edges of the skull for BPD measurement (large white dots in (a)); some reference charts have been developed using different caliper placement for this measurement (e.g. outer edge to outer edge of the skull).

when the BPD is used; in these cases, HC measurements are more reliable<sup>20</sup>.

#### *Head circumference (HC)*

*Anatomy.* As described for the BPD, ensuring that the circumference placement markers correspond to the technique described on the reference chart.

*Caliper placement.* If the ultrasound equipment has ellipse measurement capacity, then the HC can be measured directly by placing the ellipse around the outside of the skull bone echoes (Figure 1). Alternatively, the HC can be calculated from the BPD and occipitofrontal diameter (OFD) as follows: the BPD is measured using a leading edge technique as described in the previous section whereas the OFD is obtained by placing the calipers in the middle of the bone echo at both the frontal and occipital skull bones. HC is then calculated using the equation:  $HC = 1.62 \times (BPD + OFD)$ .

#### *Abdominal circumference (AC)*

*Anatomy.*

- Transverse section of the fetal abdomen (as circular as possible);
- umbilical vein at the level of the portal sinus;
- stomach bubble visualized;
- kidneys should not be visible.

*Caliper placement.* The AC is measured at the outer surface of the skin line, either directly with ellipse calipers or calculated from linear measurements made perpendicular to each other, usually the anteroposterior abdominal diameter (APAD) and transverse abdominal diameter (TAD) (Figure 1). To measure the APAD, the calipers are placed on the outer borders of the body outline, from the posterior aspect (skin covering the spine) to the anterior abdominal wall. To measure the TAD, the calipers are placed on the outer borders of the body outline, across the abdomen at the widest point. The AC is then calculated using the formula:  $AC = \pi (APAD + TAD)/2 = 1.57 (APAD + TAD)$ .

#### *Femur diaphysis length (FDL)*

*Anatomy.* The FDL is imaged optimally with both ends of the ossified metaphysis clearly visible<sup>21,22</sup>. The longest axis of the ossified diaphysis is measured. The same technique as that used to establish the reference chart should be used with regard to the angle between the femur and the insonating ultrasound beams. An angle of insonation between 45° and 90° is typical.

*Caliper placement.* Each caliper is placed at the ends of the ossified diaphysis without including the distal femoral epiphysis if it is visible (Figure 1). This measurement should exclude triangular spur artifacts that can falsely extend the diaphysis length.

#### *Estimated fetal weight (EFW)*

Mid-trimester sonographic measurements can be used to identify abnormalities of fetal size<sup>23,24</sup>. Some countries also use this information to estimate fetal weight as a baseline parameter for the detection of subsequent growth problems. Many 'size discrepancies' are explained by incorrect menstrual age estimates, even in women with 'certain dates'<sup>25,26</sup>. If gestational age is determined at an earlier scan, EFW can be compared to dedicated normal, preferably local, reference ranges for this parameter<sup>14,27,28</sup>. However, the degree of deviation from normal at this early stage of pregnancy that would justify action (e.g. follow-up scan to assess fetal growth or fetal chromosomal analysis) has not been firmly established.

#### *Amniotic fluid assessment*

Amniotic fluid volume can be estimated subjectively or using sonographic measurements. Subjective estimation is not inferior to the quantitative measurement techniques (e.g. deepest pocket, amniotic fluid index) when performed by experienced examiners<sup>29,30</sup>. Patients with deviations from normal should have more detailed anatomical evaluation and clinical follow-up.

#### *Fetal movement*

Normal fetuses typically have a relaxed position and show regular movements. There are no specific movement patterns at this stage of pregnancy. Temporary absence or reduction of fetal movements during the scan should not be considered as a risk factor<sup>31</sup>. Abnormal positioning or unusually restricted or persistently absent fetal movements may suggest abnormal fetal conditions such as arthrogryposis<sup>32</sup>. The biophysical profile is not considered part of a routine mid-trimester scan<sup>33</sup>.

#### *Doppler ultrasonography*

The application of Doppler techniques is not currently recommended as part of the routine second-trimester ultrasound examination. There is insufficient evidence to support universal use of uterine or umbilical artery Doppler evaluation for the screening of low-risk pregnancies<sup>34–36</sup>.

#### *Multiple gestation*

The evaluation of multiple pregnancies should include the following additional elements:

- visualization of the placental cord insertion;
- distinguishing features (gender, unique markers, position in uterus);
- determination of chorionicity is sometimes feasible in the second trimester if there are clearly two separate placental masses and discordant genders. Chorionicity is much better evaluated before 14–15 weeks (lambda sign or T-sign).

Abnormalities of umbilical cord insertion into the placenta, such as velamentous cord insertion, are more

common in multiple gestations and can be associated with several pregnancy complications, such as fetal growth restriction, vasa previa and abnormal fetal heart rate patterns<sup>37,38</sup>. Unfortunately, many cases of vasa previa may not be recognized during pregnancy<sup>39</sup>.

Follow-up of multiple pregnancies should be arranged in accordance with local guidelines and clinical practices.

### Anatomical survey

Recommended minimum requirements for a basic fetal anatomical survey during the mid-trimester of pregnancy are summarized in Table 1.

#### Head

**Skull.** Four areas of the fetal skull should be evaluated routinely: size, shape, integrity and bone density. All these characteristics can be visualized at the time of the head measurements and when the brain is evaluated for anatomical integrity (Figure 2)<sup>40</sup>.

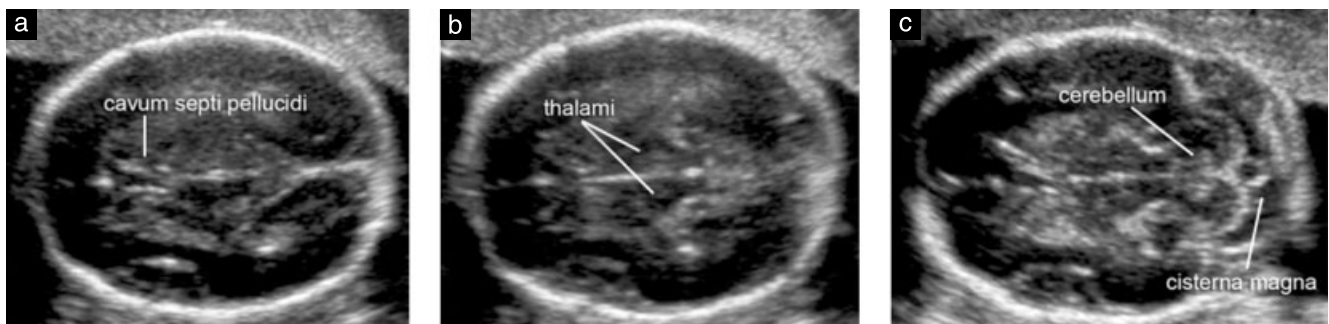
- Size: measurements are performed as mentioned in the biometry section.
- Shape: the skull normally has an oval shape without focal protrusions or defects and is interrupted only by narrow echolucent sutures. Alterations of shape (e.g. lemon, strawberry, cloverleaf) should be documented and investigated<sup>41</sup>.
- Integrity: no bony defects should be present. Rarely, brain tissue can extrude through defects of the frontal or occipital bones, although cephaloceles may occur at other sites as well.
- Density: normal skull density is manifested as a continuous echogenic structure that is interrupted only by cranial sutures in specific anatomical locations. The absence of this whiteness or extreme visibility of the fetal brain should raise suspicion of poor mineralization (e.g. osteogenesis imperfecta, hypophosphatasia)<sup>42</sup>. Poor mineralization is also suggested when the skull becomes easily depressed as a result of manual pressure from transducer placement against the maternal abdominal wall.

**Table 1** Recommended minimum requirements for basic mid-trimester fetal anatomical survey

|                |  |
|----------------|--|
| Head           | Intact cranium<br>Cavum septi pellucidi<br>Midline falx<br>Thalami<br>Cerebral ventricles<br>Cerebellum<br>Cisterna magna  |
| Face           | Both orbits present<br>Median facial profile*<br>Mouth present<br>Upper lip intact   |
| Neck           | Absence of masses (e.g. cystic hygroma)  |
| Chest/Heart    | Normal appearing shape/size of chest and lungs<br>Heart activity present<br>Four-chamber view of heart in normal position<br>Aortic and pulmonary outflow tracts*<br>No evidence of diaphragmatic hernia |
| Abdomen        | Stomach in normal position<br>Bowel not dilated<br>Both kidneys present<br>Cord insertion site   |
| Skeletal       | No spinal defects or masses (transverse and sagittal views)<br>Arms and hands present, normal relationships<br>Legs and feet present, normal relationships   |
| Placenta       | Position<br>No masses present<br>Accessory lobe  |
| Umbilical cord | Three-vessel cord*   |
| Genitalia      | Male or female*  |

\*Optional component of checklist: can be evaluated if technically feasible.

**Brain.** Standard scanning planes for the basic examination of the fetal brain have already been described in an ISUOG guideline document<sup>19</sup> which can be downloaded from the Society's website (<http://www.isuog.org>). Two axial planes permit visualization of the cerebral structures relevant to the anatomical integrity of the brain. These planes are commonly referred to as the transventricular and transthalamic planes (Figure 2). Imaging artifacts may obscure the hemisphere closest to the transducer. A third axial transcerebellar plane can be added to evaluate



**Figure 2** Transverse views of the fetal head demonstrating standard transventricular (a), transthalamic (b) and transcerebellar (c) scanning planes. The first two planes allow assessment of the anatomical integrity of the brain. The third permits evaluation of the cerebellum and cisterna magna in the posterior fossa.

the posterior fossa. The following brain structures should be evaluated:

- lateral ventricles (including choroid plexi);
- cavum septi pellucidi;
- midline falx;
- thalami;
- cerebellum;
- cisterna magna.

### Face

Minimum evaluation of the fetal face should include an attempt to visualize the upper lip for possible cleft lip anomaly<sup>43</sup> (Figure 3a). If technically feasible, other facial features that can be assessed include the median facial profile (Figure 3b), orbits (Figure 3c), nose and nostrils.

### Neck

The neck normally appears as cylindrical with no protuberances, masses or fluid collections<sup>44</sup>. Obvious neck masses such as cystic hygromas or teratomas should be documented.

### Thorax

The shape should be regular with a smooth transition to the abdomen<sup>45</sup>. The ribs should have normal curvature without deformities. Both lungs should appear homogeneous and without evidence of mediastinal shift or masses. The diaphragmatic interface can often be visualized as a hypoechoic dividing line between the thoracic and abdominal content (e.g. liver and stomach)<sup>46,47</sup>.

### Heart

*General considerations for cardiac examination.* The basic and extended basic cardiac ultrasonographic examinations are designed to maximize the detection of congenital heart disease during a second-trimester scan (Figure 4)<sup>48</sup>. A single acoustic focal zone and relatively

narrow field of view can help to maximize frame rates. Images should be magnified until the heart fills at least a third to half of the display screen.

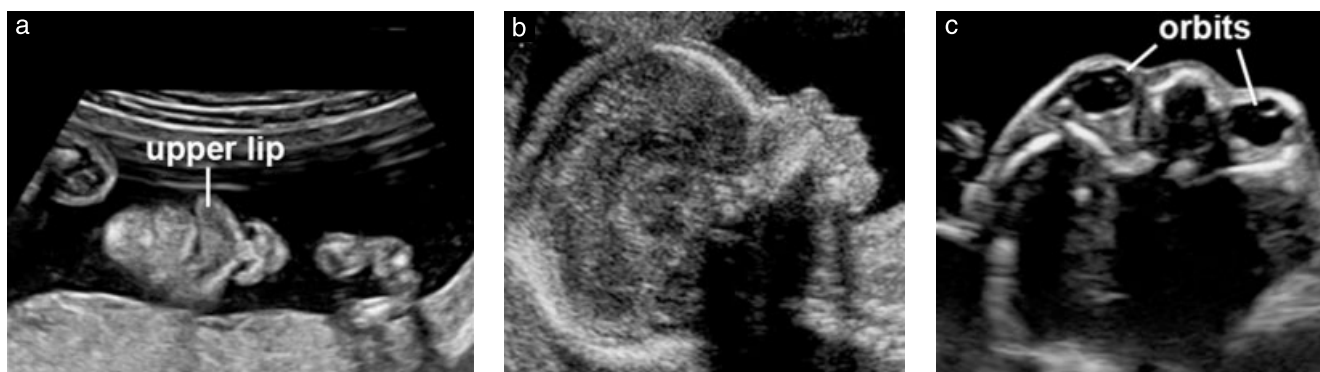*Basic cardiac examination.* The basic cardiac screening examination is interpreted from a four-chamber view of the fetal heart. A normal regular rate ranges from 120 to 160 beats per min. The heart should be located in the left chest (same side as the fetal stomach) if the *situs* is normal. A normal heart is usually no larger than one-third of the area of the chest and is without pericardial effusion. The heart is normally deviated by about  $45 \pm 20^\circ$  (2 SD) towards the left side of the fetus<sup>49</sup>.

*Extended basic cardiac examination.* An extended basic cardiac evaluation, which includes the aortic and pulmonary outflow tracts, can increase the detection rates for major cardiac malformations above those achievable by the four-chamber view alone. Views additional to those of the basic examination are more likely to identify conotruncal anomalies such as tetralogy of Fallot, transposition of the great arteries, double outlet right ventricle and truncus arteriosus. Normal great vessels are approximately equal in size and should cross each other as they exit from their respective ventricular chambers.

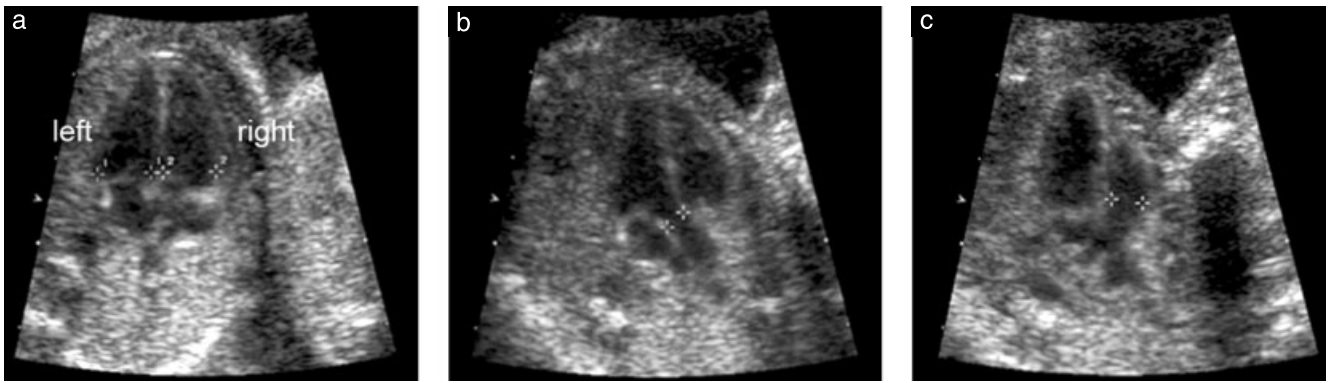
Some investigators have described an optional 'three-vessels and trachea view' that may also be useful for evaluating the pulmonary artery, ascending aorta and right superior vena cava, in terms of their relative sizes and anatomical relationships<sup>50</sup>. For a more detailed description of fetal cardiac screening, the reader is referred to the ISUOG guidelines for the fetal cardiac examination. This document can be downloaded from the Society's website<sup>48</sup> (<http://www.isuog.org>).

### Abdomen

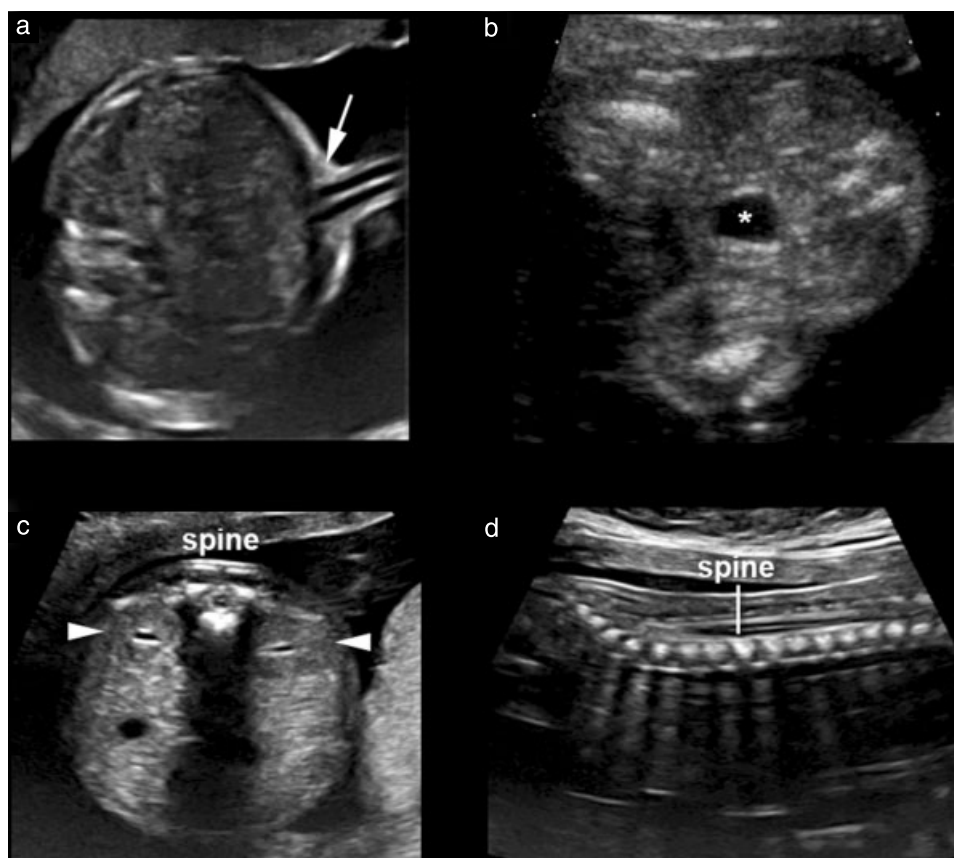
Abdominal organ *situs* should be determined<sup>51</sup>. The fetal stomach should be identified in its normal position on the left side. Bowel should be contained within the abdomen and the umbilical cord should insert into an intact abdominal wall. Abnormal fluid collections of the bowel (e.g. enteric cysts, obvious bowel dilatation) should



**Figure 3** Ultrasound imaging of the fetal face. The mouth, lips and nose are typically evaluated in a coronal view (a). If technically feasible, a median facial profile provides important diagnostic clues for cleft lip, frontal bossing, micrognathia and nasal bone anomalies (b). Both fetal orbits should appear symmetrical and intact (c).



**Figure 4** Basic and extended basic views of the fetal heart. The basic cardiac scan is obtained from a four-chamber view (a) when both ventricles are seen during end diastole (calipers). An extended basic scan of the great arteries demonstrates the left (b) and right (c) ventricular outflow tracts. Separate arterial outflow tracts (calipers), approximately equal in size, exit their respective ventricles by crossing over each other in normal fetuses.



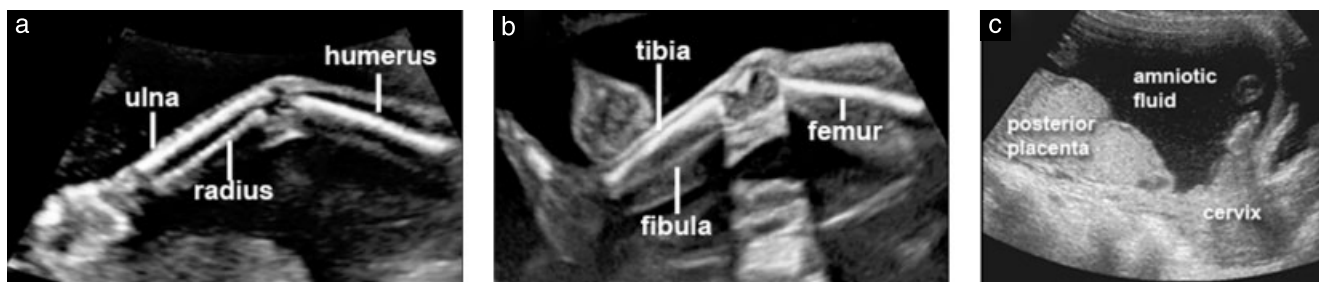**Figure 5** Ultrasound imaging of the fetal cord insertion site, bladder with umbilical arteries, kidneys and spine. The umbilical cord insertion site into the fetal abdomen (a, arrow) provides information about the presence of ventral wall defects such as omphalocele or gastroschisis. The fetal bladder (b, \*) and both kidneys (c, arrowheads) should be identified. Axial and longitudinal views of the spine provide effective screening for spina bifida, especially when these scanning planes are abnormal in the presence of frontal skull deformation and an obliterated cisterna magna (c,d).

be documented. Aside from the left-sided stomach, a fetal gallbladder may be seen in the right upper quadrant next to the liver, although this latter finding is not a minimum requirement of the basic scan. Any other cystic structures seen in the abdomen should prompt referral for a more detailed scan. The fetal umbilical cord insertion (Figure 5a) site should be examined for evidence of a ventral wall defect such as omphalocele or gastroschisis.

Cord vessels may also be counted using gray-scale imaging as an optional component of the routine anatomical survey.

#### *Kidneys and bladder*

The fetal bladder and both kidneys should be identified (Figures 5b and 5c). If either bladder or renal pelvis appears enlarged, a measurement should be documented.



**Figure 6** Sonography of the fetal upper extremities, lower extremities and placenta. The presence or absence of the upper and lower limbs should be documented routinely unless they are poorly visualized due to technical factors (a, b). Placental position should be determined in relation to the maternal cervix (c).

Persistent failure to visualize the bladder should prompt referral for a more detailed assessment.

### Spine

A satisfactory examination of the fetal spine requires expertise and meticulous scanning, and the results are heavily dependent upon fetal position (Figures 5c and 5d). Complete evaluation of the fetal spine from every projection is not part of the basic examination, although transverse and sagittal views are usually informative. The most frequent of the severe spinal abnormalities, open spina bifida, is usually associated with abnormal intracranial anatomy such as a characteristic cerebellar deformity (banana sign) and obliterated cisterna magna. Other views of the fetal spine may identify other spinal malformations, including vertebral abnormalities and sacral agenesis<sup>19</sup>.

### Limbs and extremities

The presence or absence of both arms/hands (Figure 6a) and both legs/feet (Figure 6b) should be documented using a systematic approach<sup>52</sup>. Counting fingers or toes is not required as part of the routine mid-trimester scan.

### Placenta

During ultrasonography, the placental location (Figure 6c), its relationship with the internal cervical os and its appearance should be described. Examples of abnormal placental findings include the presence of hemorrhage, multiple cysts with triploidy and placental masses such as chorioangioma. In most cases of the routine second-trimester examination, transabdominal ultrasonography permits clear definition of the relationship between placenta and internal cervical os. If the lower placental edge reaches or overlaps the internal os, a follow-up examination in the third trimester is recommended<sup>53,54</sup>.

Women with a history of uterine surgery and low anterior placenta or placenta previa are at risk for placental attachment disorders. In these cases, the placenta should be examined for findings of accreta, the most sensitive of which are the presence of multiple irregular placental lacunae that show arterial or mixed flow<sup>55,56</sup>. Abnormal appearance of the uterine wall–bladder wall interface is quite specific for accreta, but is seen in few

cases. Loss of the echolucent space between an anterior placenta and the uterine wall is neither a sensitive nor a specific marker for placenta accreta. Although placenta accreta may be suspected during a routine mid-trimester scan, a more detailed evaluation is usually required to further examine this possibility.

### Genitalia

Characterization of external genitalia to determine fetal gender is not considered mandatory in the context of a mid-trimester routine scan. Reporting of gender should be considered only with parental consent and in the context of local practices.

### Cervix, uterine morphology and adnexa

Several studies have demonstrated a strong correlation between short cervical length on transvaginal scan and subsequent preterm birth. However, several randomized controlled trials that examined the combination of routine cervical length measurement and subsequent interventions (cerclage, progesterone) failed to demonstrate conclusively any cost-effectiveness of such screening programs<sup>57,58</sup>. Currently, there is insufficient evidence to recommend routine cervical length measurements at the mid trimester in an unselected population<sup>59</sup>.

Identification of women with short cervical length may have significant benefits for research purposes and further intervention studies, but this is not a justification for routine cervical scanning. Such a universal screening program would not only require significant resources and quality assurance, but also cause potential disadvantages by introducing anxiety and unnecessary intervention.

Uterine fibroids and adnexal masses should be documented if they are likely to interfere with labor<sup>60</sup>.

## REFERENCES

1. World Health Organization. *Report on the Regional Consultation Towards the Development of a Strategy for Optimizing Fetal Growth and Development*. WHO Regional Office for the Eastern Mediterranean: Cairo, 2005.
2. Barker DJ, Gluckman PD, Godfrey KM, Harding JE, Owens JA, Robinson JS. Fetal nutrition and cardiovascular disease in adult life. *Lancet* 1993; 341: 938–91.



3. Schwarzler P, Senat MV, Holden D, Bernard JP, Masroor T, Ville Y. Feasibility of the second-trimester fetal ultrasound examination in an unselected population at 18, 20 or 22 weeks of pregnancy: a randomized trial. *Ultrasound Obstet Gynecol* 1999; **14**: 92–97.
4. Saltvedt S, Almstrom H, Kublickas M, Valentin L, Grunewald C. Detection of malformations in chromosomally normal fetuses by routine ultrasound at 12 or 18 weeks of gestation – a randomised controlled trial in 39,572 pregnancies. *BJOG* 2006; **113**: 664–674.
5. Tegnander E, Williams W, Johansen OJ, Blaas HG, Eik-Nes SH. Prenatal detection of heart defects in a non-selected population of 30149 fetuses – detection rates and outcome. *Ultrasound Obstet Gynecol* 2006; **27**: 252–265.
6. Goldberg JD. Routine screening for fetal anomalies: expectations. *Obstet Gynecol Clin North Am* 2004; **31**: 35–50.
7. Grandjean H, Larroque D, Levi S. The performance of routine ultrasonographic screening of pregnancies in the Eurofetus Study. *Am J Obstet Gynecol* 1999; **181**: 446–454.
8. World Health Organization. *Training in Diagnostic Ultrasound: Essentials, Practice, and Standards*. (WHO Technical Report Series, No. 875). WHO: Geneva, 1998.
9. Reddy UM, Filly RA, Copel JA. Prenatal imaging: ultrasonography and magnetic resonance imaging. *Obstet Gynecol* 2008; **112**: 145–157.
10. Ville Y. ‘Ceci n’est pas une échographie’: a plea for quality assessment in prenatal ultrasound. *Ultrasound Obstet Gynecol* 2008; **31**: 1–5.
11. Abramowicz JS, Kossoff G, Marsal K, Ter Haar G. Safety Statement, 2000 (reconfirmed 2003). International Society of Ultrasound in Obstetrics and Gynecology (ISUOG). *Ultrasound Obstet Gynecol* 2003; **21**: 100.
12. Altman DG, Chitty LS. New charts for ultrasound dating of pregnancy. *Ultrasound Obstet Gynecol* 1997; **10**: 174–191.
13. Degani S. Fetal biometry: clinical, pathological, and technical considerations. *Obstet Gynecol Surv* 2001; **56**: 159–167.
14. Dudley NJ. A systematic review of the ultrasound estimation of fetal weight. *Ultrasound Obstet Gynecol* 2005; **25**: 80–89.
15. Salomon LJ, Bernard JP, Duyme M, Doris B, Mas N, Ville Y. Feasibility and reproducibility of an image scoring method for quality control of fetal biometry in the second trimester. *Ultrasound Obstet Gynecol* 2006; **27**: 34–40.
16. Salomon LJ, Bernard JP, Duyme M, Buvat I, Ville Y. The impact of choice of reference charts and equations on the assessment of fetal biometry. *Ultrasound Obstet Gynecol* 2005; **25**: 559–565.
17. Hadlock FP, Harrist RB, Shah YP, King DE, Park SK, Sharman RS. Estimating fetal age using multiple parameters: a prospective evaluation in a racially mixed population. *Am J Obstet Gynecol* 1987; **156**: 955–957.
18. Taipale P, Hiilesmaa V. Predicting delivery date by ultrasound and last menstrual period in early gestation. *Obstet Gynecol* 2001; **97**: 189–194.
19. International Society of Ultrasound in Obstetrics and Gynecology. Sonographic examination of the fetal central nervous system: guidelines for performing the ‘basic examination’ and the ‘fetal neurosonogram’. *Ultrasound Obstet Gynecol* 2007; **29**: 109–116.
20. Hadlock FP, Deter RL, Carpenter RJ, Park SK. Estimating fetal age: effect of head shape on BPD. *AJR Am J Roentgenol* 1981; **137**: 83–85.
21. Jago JR, Whittingham TA, Heslop R. The influence of ultrasound scanner beam width on femur length measurements. *Ultrasound Med Biol* 1994; **20**: 699–703.
22. Lessoway VA, Schulzer M, Wittmann BK. Sonographic measurement of the fetal femur: factors affecting accuracy. *J Clin Ultrasound* 1990; **18**: 471–476.
23. Hadlock FP, Harrist RB, Sharman RS, Deter RL, Park SK. Estimation of fetal weight with the use of head, body, and femur measurements – a prospective study. *Am J Obstet Gynecol* 1985; **151**: 333–337.
24. Mongelli M, Ek S, Tambyrajia R. Screening for fetal growth restriction: a mathematical model of the effect of time interval and ultrasound error. *Obstet Gynecol* 1998; **92**: 908–912.
25. Tuñón K, Eik-Nes SH, Grøttum P. Fetal outcome when the ultrasound estimate of the day of delivery is more than 14 days later than the last menstrual period estimate. *Ultrasound Obstet Gynecol* 1999; **14**: 17–22.
26. Tuñón K, Eik-Nes SH, Grøttum P. A comparison between ultrasound and a reliable last menstrual period as predictors of the day of delivery in 15000 examinations. *Ultrasound Obstet Gynecol* 1996; **8**: 178–185.
27. Johnsen SL, Rasmussen S, Wilsgaard T, Sollien R, Kiserud T. Longitudinal reference ranges for estimated fetal weight. *Acta Obstet Gynecol Scand* 2006; **85**: 286–297.
28. Salomon LJ, Bernard JP, Ville Y. Estimation of fetal weight: reference range at 20–36 weeks’ gestation and comparison with actual birth-weight reference range. *Ultrasound Obstet Gynecol* 2007; **29**: 550–555.
29. Magann EF, Chauhan SP, Whitworth NS, Isler C, Wiggs C, Morrison JC. Subjective versus objective evaluation of amniotic fluid volume of pregnancies of less than 24 weeks’ gestation: how can we be accurate? *J Ultrasound Med* 2001; **20**: 191–195.
30. Magann EF, Perry KG Jr, Chauhan SP, Anfanger PJ, Whitworth NS, Morrison JC. The accuracy of ultrasound evaluation of amniotic fluid volume in singleton pregnancies: the effect of operator experience and ultrasound interpretative technique. *J Clin Ultrasound* 1997; **25**: 249–253.
31. de Vries JI, Fong BF. Normal fetal motility: an overview. *Ultrasound Obstet Gynecol* 2006; **27**: 701–711.
32. Bonilla-Musoles F, Machado LE, Osborne NG. Multiple congenital contractures (congenital multiple arthrogryposis). *J Perinat Med* 2002; **30**: 99–104.
33. Manning FA. Fetal biophysical profile. *Obstet Gynecol Clin North Am* 1999; **26**: 557–77.
34. Alfirevic Z, Neilson JP. The current status of Doppler sonography in obstetrics. *Curr Opin Obstet Gynecol* 1996; **8**: 114–118.
35. Neilson JP, Alfirevic Z. Doppler ultrasound for fetal assessment in high-risk pregnancies. *Cochrane Database Syst Rev* 2000; CD000073.
36. Alfirevic Z, Stampalija T, Gyte GM. Fetal and umbilical Doppler ultrasound in high-risk pregnancies. *Cochrane Database Syst Rev* 2010; CD007529.
37. Heinonen S, Ryyänen M, Kirkinen P, Saarikoski S. Perinatal diagnostic evaluation of velamentous umbilical cord insertion: clinical, Doppler, and ultrasonic findings. *Obstet Gynecol* 1996; **87**: 112–117.
38. Pretorius DH, Chau C, Poeltler DM, Mendoza A, Catanzarite VA, Hollenbach KA. Placental cord insertion visualization with prenatal ultrasonography. *J Ultrasound Med* 1996; **15**: 585–593.
39. Gagnon R, Morin L, Bly S, Butt K, Cargill YM, Denis N, Hietala-Coyle MA, Lim KI, Ouellet A, Raciot MH, Salem S; Diagnostic Imaging Committee, Hudon L, Basso M, Bos H, Delisle MF, Farine D, Grabowska K, Menticoglou S, Mundle W, Murphy-Kaulbeck L, Pressey T, Roggensack A; Maternal Fetal Medicine Committee. Guidelines for the management of vasa previa. *Obstet Gynaecol Can* 2009; **31**: 748–760.
40. Aubry MC, Aubry JP, Dommergues M. Sonographic prenatal diagnosis of central nervous system abnormalities. *Childs Nerv Syst* 2003; **19**: 391–402.
41. Miller C, Losken HW, Towbin R, Bowen A, Mooney MP, Towbin A, Faix RS. Ultrasound diagnosis of craniosynostosis. *Cleft Palate Craniofac J* 2002; **39**: 73–80.
42. Brown BS. The prenatal ultrasonographic diagnosis of osteogenesis imperfecta lethalis. *J Can Assoc Radiol* 1984; **35**: 63–66.
43. Rotten D, Levaillant JM. Two- and three- dimensional sonographic assessment of the fetal face. 1. A systematic analysis of the normal face. *Ultrasound Obstet Gynecol* 2004; **23**: 224–231.
44. Dar P, Gross SJ. Craniofacial and neck anomalies. *Clin Perinatol* 2000; **27**: 813–837.

45. Azouz EM, Teebi AS, Eydoux P, Chen MF, Fassier F. Bone dysplasias: an introduction. *Can Assoc Radiol J* 1998; 49: 105–109.
46. Ruano R, Benachi A, Aubry MC, Bernard JP, Hameury F, Nihoul-Fekete C, Dumez Y. Prenatal sonographic diagnosis of congenital hiatal hernia. *Prenat Diagn* 2004; 24: 26–30.
47. Blaas HG, Eik-Nes SH. Sonographic development of the normal foetal thorax and abdomen across gestation. *Prenat Diagn* 2008; 28: 568–580.
48. International Society of Ultrasound in Obstetrics and Gynecology. Cardiac screening examination of the fetus: guidelines for performing the 'basic' and 'extended basic' cardiac scan. *Ultrasound Obstet Gynecol* 2006; 27: 107–113.
49. Comstock CH. Normal fetal heart axis and position. *Obstet Gynecol* 1987; 70: 255–259.
50. Yagel S, Arbel R, Anteby EY, Raveh D, Achiron R. The three vessels and trachea view (3VT) in fetal cardiac scanning. *Ultrasound Obstet Gynecol* 2002; 20: 340–345.
51. Bronshtein M, Gover A, Zimmer EZ. Sonographic definition of the fetal situs. *Obstet Gynecol* 2002; 99: 1129–1130.
52. Holder-Espinasse M, Devisme L, Thomas D, Boute O, Vaast P, Fron D, Herbaux B, Puech F, Manouvrier-Hanu S. Pre- and postnatal diagnosis of limb anomalies: a series of 107 cases. *Am J Med Genet A* 2004; 124A: 417–422.
53. Bhide A, Thilaganathan B. Recent advances in the management of placenta previa. *Curr Opin Obstet Gynecol* 2004; 16: 447–451.
54. Royal College of Obstetricians and Gynaecologists. Guideline No. 27. *Placenta Praevia and Placenta Praevia Accreta: Diagnosis and Management*. RCOG: London, October, 2005.
55. Finberg HJ, Williams JW. Placenta accreta: prospective sonographic diagnosis in patients with placenta previa and prior cesarean section. *J Ultrasound Med* 1992; 11: 333–343.
56. Comstock CH, Love JJ Jr, Bronsteen RA, Lee W, Vettrano IM, Huang RR, Lorenz RP. Sonographic detection of placenta accreta in the second and third trimesters of pregnancy. *Am J Obstet Gynecol* 2004; 190: 1135–1140.
57. Fonseca EB, Celik E, Parra M, Singh M, Nicolaides KH. Progesterone and the risk of preterm birth among women with a short cervix. *N Engl J Med* 2007; 357: 462–469.
58. To MS, Alfirevic Z, Heath VC, Cicero S, Cacho AM, Williamson PR, Nicolaides KH. Cervical cerclage for prevention of preterm delivery in women with short cervix: randomised controlled trial. *Lancet* 2004; 363: 1849–1853.
59. Berghella V, Baxter JK, Hendrix NW. Cervical assessment by ultrasound for preventing preterm delivery. *Cochrane Database Syst Rev* 2009; CD007235.
60. Qidwai GI, Caughey AB, Jacoby AF. Obstetric outcomes in women with sonographically identified uterine leiomyomata. *Obstet Gynecol* 2006; 107: 376–382.

## ACKNOWLEDGMENTS

These guidelines were developed by the Prenatal Ultrasound Screening Task Force under the auspices of the ISUOG Clinical Standards Committee; Chair, Dr Wesley Lee, Department of Obstetrics and Gynecology, Oakland University William Beaumont School of Medicine, Rochester, Michigan, USA

**Appreciation is particularly extended to specialty consultants who contributed to this project:**

**Task Force Chair: Laurent J Salomon, MD, PhD**  
*Hôpital Necker Enfants Malades, AP-HP, Université Paris Descartes, Paris, France*

**Zarko Alfirevic, MD**  
*Division of Perinatal and Reproductive Medicine, University of Liverpool, Liverpool Women's Hospital, Liverpool, UK*

**Vincenzo Berghella, MD**  
*Department of Obstetrics and Gynecology, Thomas Jefferson University, Philadelphia, PA, USA*

**Caterina Bilardo, MD**  
*Department of Obstetrics and Gynecology, Academic Medical Centre, Amsterdam, The Netherlands*

**Edgar Hernandez-Andrade, MD**  
*Department of Maternal Fetal Medicine, National Institute of Perinatal Medicine, Mexico City, Mexico*

**Synnove Lian Johnsen, MD**  
*Haukeland University Hospital, Bergen, Norway*

**Karim Kalache, MD**  
*Department of Obstetrics, Charité University Hospital-Campus Mitte, Berlin, Germany*

**Wesley Lee, MD**  
*Division of Fetal Imaging, William Beaumont Hospital, Royal Oak, MI, USA*

**Kwok Yin Leung, MD**  
*Department of Obstetrics and Gynecology, Queen Mary Hospital, The University of Hong Kong, Hong Kong, China*

**Gustavo Malinger, MD**  
*Fetal Neurology Clinic, Department of Obstetrics and Gynecology, Wolfson Medical Center, Tel-Aviv University, Israel*

**Hernan Munoz, MD**  
*Department of Obstetrics and Gynecology, Universidad de Chile, Clinica Las Condes, Santiago, Chile*

**Federico Prefumo, MD, PhD**  
*Department of Obstetrics and Gynecology, University of Brescia, Brescia, Italy*

**Ants Toi, MD**  
*Mount Sinai Hospital, Department of Medical Imaging, University of Toronto, Toronto, Canada*

Special appreciation to Jacques Abramowicz (USA), MD, PhD, for his contribution to the Safety section and to Jean-Philippe Bault (France), MD, for providing some of the images.

**Copies of this document are available at:**  
<http://www.isuog.org>

ISUOG Secretariat  
 Unit 4, Blythe Mews  
 Blythe Road  
 London W14 0HW, UK  
 e-mail: info@isuog.org

## Mid-Trimester Fetal Ultrasound Scan Report Form

|   |  |  |                                |
|---|--|--|--------------------------------|
| <b>Patient:</b> _____   |  | <b>ID number:</b> _____  |                                |
| Date of birth (DD/MM/YYYY): _____<br>Referring physician: _____<br>Date of exam (DD/MM/YYYY): _____<br>Sonographer / Supervisor: _____  |  | <b>Indication for scan and relevant clinical information:</b>  |                                |
|   |  | <b>Gestational age (W + D):</b><br>Based on: <i>LMP</i> / <i>Previous US</i> / <i>Other</i> :  |                                |
|   |  | <b>Technical conditions:</b> <i>Good</i> / <i>Limited by:</i><br>Singleton / Multiple (use 1 sheet/fetus)<br>=> <b>Chorionicity:</b> |                                |
| <b>PLACENTA:</b> Position:  |  |  |                                |
| Relation to cervical os: <input type="checkbox"/> clear <input type="checkbox"/> covering _____ mm from os<br>Appearance <input type="checkbox"/> Normal <input type="checkbox"/> Abnormal*   |  |  |                                |
| <b>AMNIOTIC FLUID:</b> <input type="checkbox"/> Normal <input type="checkbox"/> Abnormal*   |  |  |                                |
| <b>FETAL MOVEMENT:</b> <input type="checkbox"/> Normal <input type="checkbox"/> Abnormal*   |  |  |                                |
| <b>MEASUREMENTS</b>   |  | <b>mm</b>  | <b>Percentile (References)</b> |
| Biparietal diameter   |  |  |                                |
| Head circumference  |  |  |                                |
| Abdominal circumference   |  |  |                                |
| Femur diaphysis length  |  |  |                                |
| Other:  |  |  |                                |
| Other:  |  |  |                                |
| Other:  |  |  |                                |
| <b>*Abnormal findings (please detail):</b>  |  |  |                                |
|   |  |  |                                |
| <b>CONCLUSION:</b>  |  |  |                                |
| <input type="checkbox"/> Normal and complete examination.<br><input type="checkbox"/> Normal but incomplete examination.<br><input type="checkbox"/> Abnormal examination*<br><input type="checkbox"/> Plans: <input type="checkbox"/> No further ultrasound scans required.<br><input type="checkbox"/> Follow up planned in ..... weeks.<br><input type="checkbox"/> Referred to .....<br><input type="checkbox"/> Other: |  |  |                                |

| SONOGRAPHIC APPEARANCE OF FETAL ANATOMY:<br>(N=Normal; Ab=Abnormal*; NV=Not visualized)<br>Gray=optional | N | Ab* | NV |
|--|---|-----|----|
| <b>Head</b>  |   |     |    |
| Shape  |   |     |    |
| Cavum septi pellucidi  |   |     |    |
| Midline falx   |   |     |    |
| Thalami  |   |     |    |
| Lateral ventricle  |   |     |    |
| Cerebellum   |   |     |    |
| Cisterna magna   |   |     |    |
| <b>Face</b>  |   |     |    |
| Upper lip  |   |     |    |
| Median profile   |   |     |    |
| Orbits   |   |     |    |
| Nose   |   |     |    |
| Nostrils   |   |     |    |
| <b>Neck</b>  |   |     |    |
| <b>Thorax</b>  |   |     |    |
| Shape  |   |     |    |
| No masses  |   |     |    |
| <b>Heart</b>   |   |     |    |
| Heart activity   |   |     |    |
| Size   |   |     |    |
| Cardiac axis   |   |     |    |
| Four-chamber view  |   |     |    |
| Left ventricular outflow   |   |     |    |
| Right ventricular outflow  |   |     |    |
| <b>Abdomen</b>   |   |     |    |
| Stomach  |   |     |    |
| Bowel  |   |     |    |
| Kidneys  |   |     |    |
| Urinary bladder  |   |     |    |
| Abdominal cord insertion   |   |     |    |
| Cord vessels (optional)  |   |     |    |
| <b>Spine</b>   |   |     |    |
| <b>Limbs</b>   |   |     |    |
| Right arm (incl. hand)   |   |     |    |
| Right leg (incl. foot)   |   |     |    |
| Left arm (incl. hand)  |   |     |    |
| Left leg (incl. foot)  |   |     |    |
| <b>Gender (optional):</b> <input type="checkbox"/> M <input type="checkbox"/> F                          |   |     |    |
| <b>Other :</b>   |   |     |    |
|  |   |     |    |
|  |   |     |    |
|  |   |     |    |
|  |   |     |    |
|  |   |     |    |
|  |   |     |    |

|               |          |         |        |
|---------------|----------|---------|--------|
|               | Produced | Printed | Stored |
| No. of images |          |         |        |